



Lars Bjørndal

Edwina AM Kidd

# The Treatment of Deep Dentine Caries Lesions

**Abstract:** This paper discusses the excavation of deep caries lesions, focusing on indirect pulp-capping and the stepwise excavation approach. The concept of a modified and less invasive stepwise excavation is presented, based on considerations of caries pathology. The aim of the first excavation is primarily to make a change within the cariogenic environment, and not to remove carious dentine close to the pulp because this risks an iatrogenic pulp exposure. Microbiological and clinical studies have shown that the number of bacteria decrease during stepwise excavation procedures, and that lesions clinically arrest. The active, soft-yellowish, demineralized dentine turns into a darker, harder and drier demineralized dentine, resembling a slowly progressing lesion, where the carious dentine is easier to remove at the final visit. The final excavation has two aims: (i) to verify that arrestation has taken place, ie a clinical control of the tooth reactions and (ii) to remove the slowly progressing but still slightly infected discoloured demineralized dentine, before carrying out the permanent and final restoration.

**Clinical Relevance:** Knowledge of guidelines for treatment of deep dentine caries may reduce the risk of pulpal exposure.

**Dent Update 2005; 32: 402-413**

## Excavation procedures used to manage dental caries

There is no international consensus on the treatment of deep carious lesions. This can be confirmed when textbooks on cariology and restorative dentistry<sup>1,2</sup> are compared with the endodontic literature.<sup>3,4</sup> The cariology opinion aims to prevent pulpal exposure, whereas the endodontic opinion pays little attention to the possibility that a deep carious lesion might be a process that can be arrested.<sup>3</sup> Moreover, the endodontic literature does not believe in treatment concepts that permanently leave carious

tissue behind a seal, also described as the indirect pulp-capping procedure.<sup>4</sup> In this paper, methods of excavation will be discussed.

### How deep is 'a deep caries lesion'?

A deep caries lesion may be defined by the likelihood of a pulp exposure. When do dental practitioners expect that a potential pulp exposure is close? In a practice-based study,<sup>5</sup> Danish general dental practitioners were asked to judge the penetration depth of caries lesions that they would suggest as being at risk of pulpal exposure following excavation. The majority of dentists selected caries lesions where the demineralized dentine penetrated  $\frac{3}{4}$  of the entire dentine thickness, or closer, when evaluated on radiograph. The same criteria have been used in this paper.

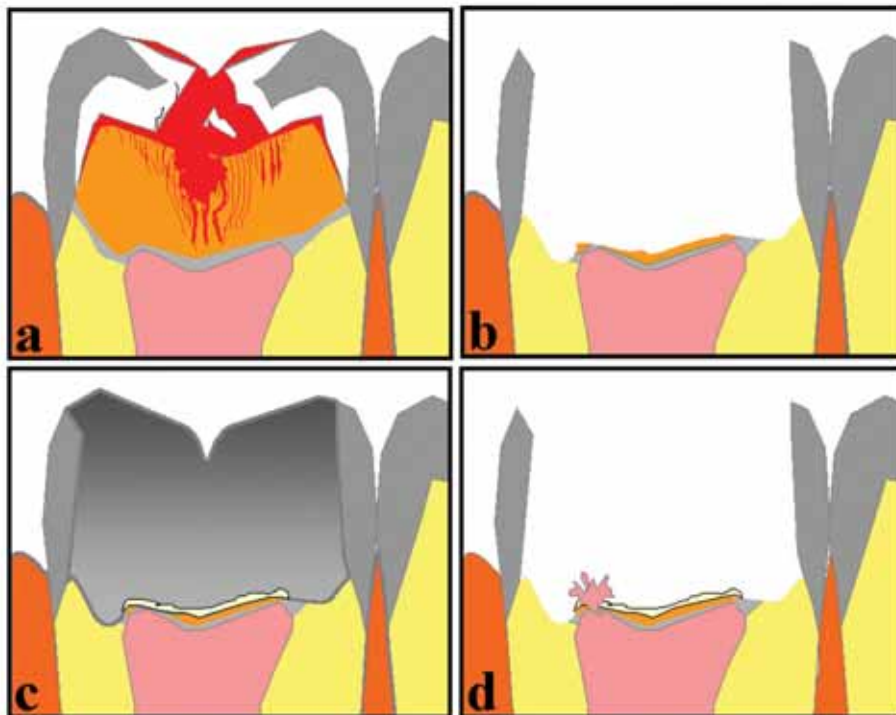
### One step procedure versus stepwise excavation procedures

Two methods have been suggested to avoid pulp exposures. These are:

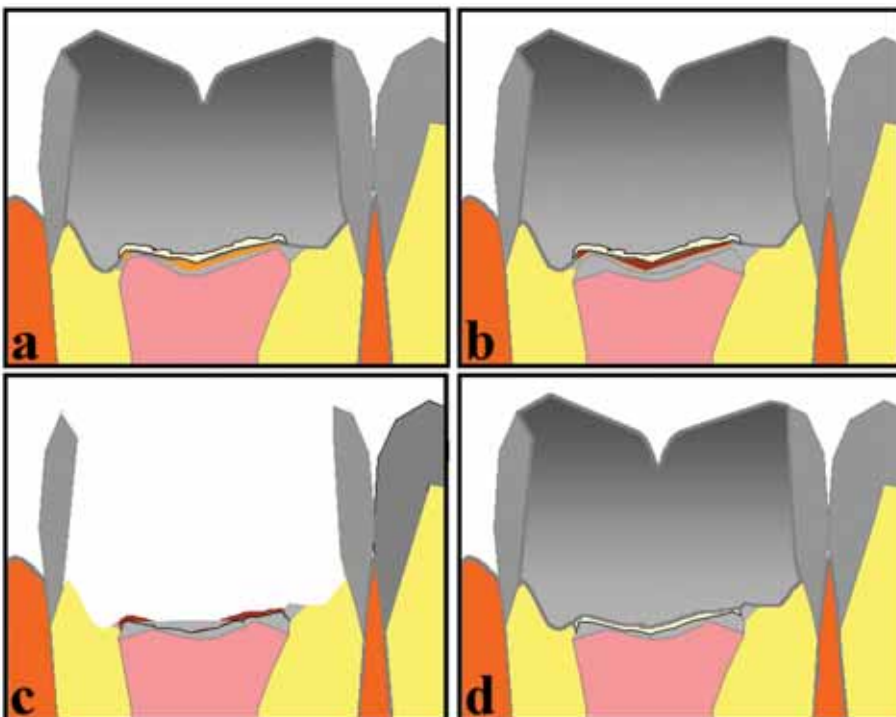
- The indirect pulp-capping procedure (Figure 1) and
- The two-stage excavation procedure or stepwise excavation (Figure 2).

It is not always made clear what the differences are between the two concepts. Therefore, a short recapitulation of the definitions is required. The indirect pulp-capping procedure almost completely removes the demineralized and discoloured dentine, leaving a thin layer of residual caries, and re-entry is not undertaken. Residual caries, as defined by Kerkhove *et al.*,<sup>6</sup> is the remaining caries at the base of a cavity which, if removed with an excavator, will certainly expose the pulp. In contrast, the stepwise excavation involves a step-by-step procedure. In Scandinavia, the first step has traditionally focused on excavation close to the residual level of caries, leaving dentine behind to facilitate a biological response from a vital pulp, whereby tertiary dentine can be produced. At re-entry (after a treatment interval of 6–8 months) the retained carious tissue is removed, with the likelihood of avoiding a perforation of the pulp because of the extra tertiary dentinal matrix laid down.<sup>1</sup>

**Lars Bjørndal**, DDS, PhD, Associate Professor, Department of Cariology and Endodontics, School of Dentistry, University of Copenhagen, 20 Nørre Allé, DK-2200 Copenhagen N, Denmark and  
**Edwina AM Kidd**, BDS, FDS RCS, PhD, DSc, Emeritus Professor of Cariology, GKT, Hillcroft, 57 Langley Avenue, Surbiton, Surrey KT6 6QR.



**Figure 1 (a–d).** The indirect pulp-capping procedure. Red zones indicate plaque: (a) before treatment; (b) after excavation with focus on pulp close excavation (residual caries). (c) No re-entry and permanent restoration are made. (d) Iatrogenic pulp exposures might be a potential risk. (From Bjørndal<sup>35</sup> reprinted with permission from Blackwell Munksgaard, Oxford.)



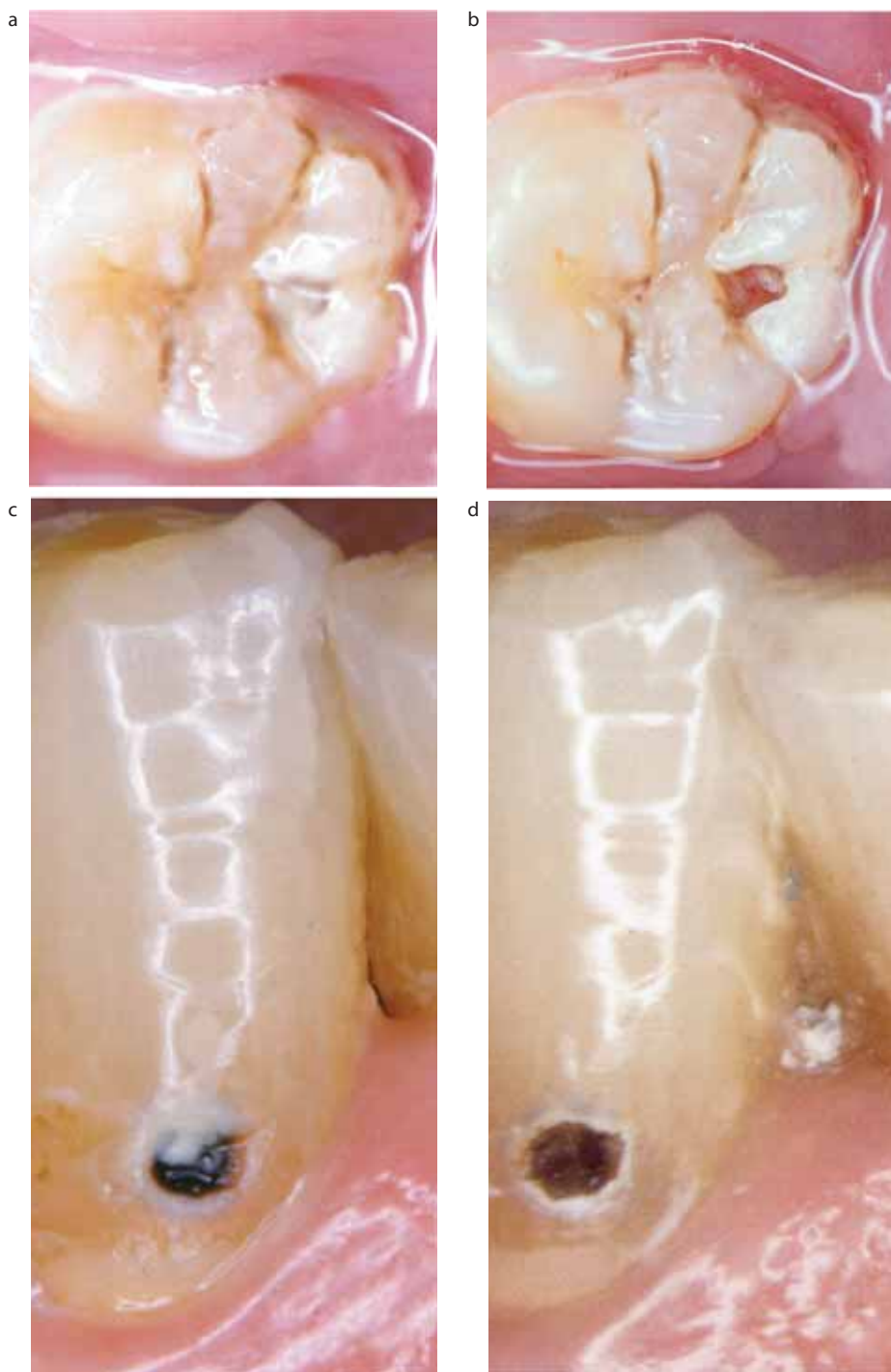
**Figure 2 (a–d).** The traditional stepwise excavation procedure: (a) after excavation to the residual level calcium hydroxide-containing base material and a provisional restoration is made; (b) after a treatment interval extra-dentinal matrix is laid down. (c) Re-entry and final excavation can be performed with the likelihood of avoiding perforation. (d) Permanent restoration. (From Bjørndal<sup>35</sup> reprinted with permission from Blackwell Munksgaard, Oxford.)

### One complete excavation procedure versus two

Two papers are often cited when stepwise excavation procedures are discussed. First, the one by Magnusson and Sundell,<sup>7</sup> treating comparable deep carious lesions in primary molars using a split mouth design where one side had a molar excavated and completed in one visit, whereas the opposite molar was stepwise excavated in two visits. A similar approach was adopted 20 years later by Leksell *et al.*,<sup>8</sup> but in this study young permanent teeth were chosen. Both studies indicated that the frequency of pulpal complications was lower following a stepwise excavation compared to one-step excavation. Therefore, excavation as a two-stage procedure seems to secure the integrity of the pulp.

### Stepwise excavation depth, length of treatment interval and outcome data

One of the earliest papers to describe a stepwise approach was the one by Sowden<sup>9</sup> in 1956. Carious tissue was removed so that it was possible to place a 1 mm thick layer of a calcium hydroxide-containing base material and an overlying temporary restoration. Re-entry and final excavation were then made after 2–3 weeks. A more rigorous approach was adopted by Magnusson and Sundell,<sup>7</sup> who said that only a thin soft layer should remain on the pulpal wall. It was not stated in detail what a thin layer meant. Presumably, they excavated as deep as they dared. They then placed a zinc-oxide eugenol cement and performed the final excavation after 4–6 weeks. This method has become common and widespread approach within the Scandinavian countries (Figure 2). Law and Lewis<sup>10</sup> gained access to all areas of carious tissue by the use of burs but gave no further details on the depth of the first excavation. A calcium hydroxide-containing base material and an amalgam restoration were placed and re-entry was made after 6 months. Eidelman *et al.*<sup>11</sup> used a slightly different method. They removed all undermined enamel in order to gain an easier access to the carious dentine along the enamel-dentine junction. At the pulpal site of the cavity approximately 1 mm of carious dentine was left adjacent to the temporary restoration, although it was not stated how the dentist determined this 1 mm depth. Re-entry was made after 1 year,



**Figure 3.** (a) A molar with an occlusal surface covered with plaque. (b) After plaque removal, light-brownish discoloration of the demineralized dentine is noted. (c) A canine with a buccal dentine exposed lesion with dark demineralized dentine, partly covered by plaque. (d) After plaque removal, a white and dull appearance of the thin enamel margins is noted.

and final excavation was performed.

It is not possible to compare these old studies because the exact clinical

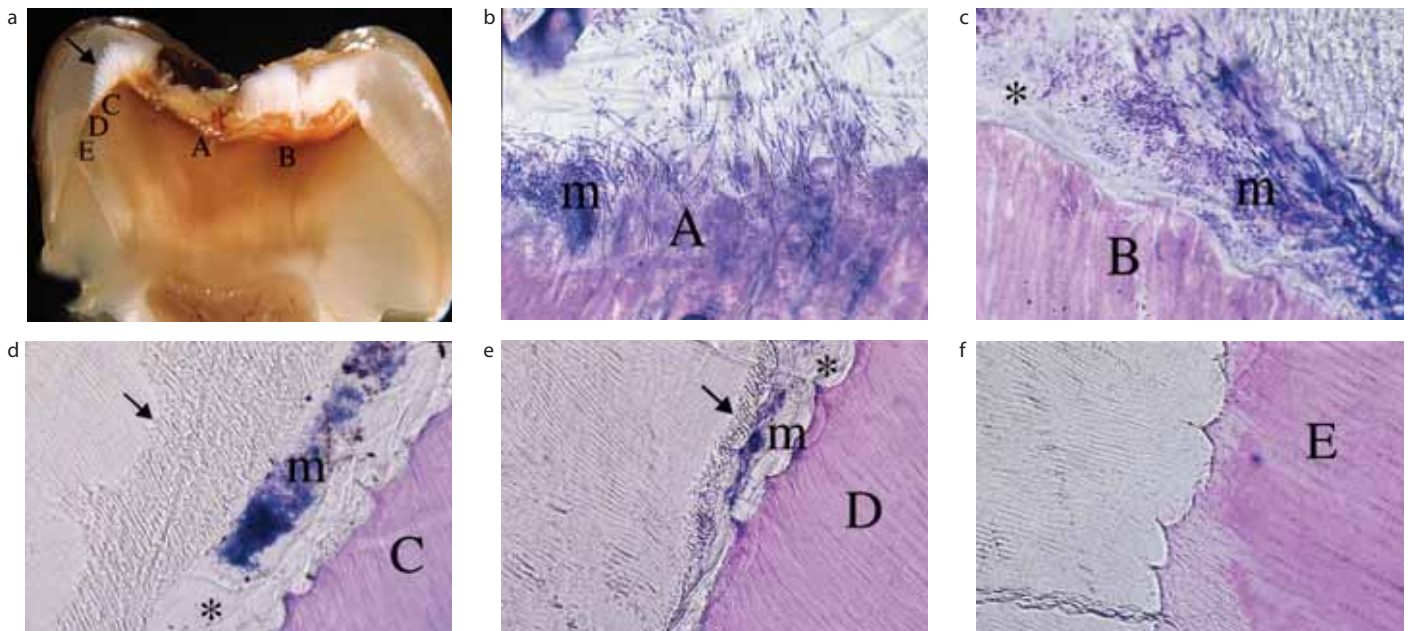
protocols differ, eg different temporary filling materials and varying times to re-entry for the second excavation. In addition,

Magnusson and Sundell treated deciduous rather than permanent teeth and no follow-up examination was made after the end of the treatment. However, 80% and 100% success was reported in the studies followed for one year.<sup>9-11</sup> This may indicate that the number of weeks/months between excavation, as well as the amount of tissue removed, may not be the critical parameters for success. However, all procedures have one factor in common, they have all changed the cariogenic environment, by removing some demineralized, infected tissue and placing a filling over what remained. This would have cut off the remaining infected dentine from the mouth.

### Update on the pathology and clinical implications

#### The principal differences between non-cavitated and cavitated dentinal carious lesions

Discoloured demineralized dentine is present in the non-cavitated progressing enamel lesion that reaches the enamel-dentine junction. From a clinical viewpoint, it is important to realize that discoloured demineralized dentine is a natural part of the progressing enamel lesion. This means that the enamel-dentine lesion can be arrested if the cariogenic biomasses at the enamel surface can be controlled. Confirming these statements, studies<sup>12,13</sup> have shown that the demineralized dentine has typically no bacterial invasion as long as the demineralized enamel is not cavitated. A lateral spread of demineralized dentine along the enamel-dentine junction is not seen in these non-cavitated lesions.<sup>14-16</sup> Thus, the general dental practitioner should not expect to find heavily infected carious dentine beneath a non-cavitated enamel lesion. This lesion does not need restoration. In addition, if we drill through an approximal surface with a white demineralized enamel lesion without any signs of a clinical surface destruction, discoloured demineralized dentine will be found. In the past, this would have indicated that the operative intervention was justified, because it would present the early lateral spread of caries. Today, the interpretation of these findings would be that an operative intervention has been made that should



**Figure 4.** (a) Tooth bisected through the central part of a cavitated and closed lesion environment. Note the undermined enamel (arrow). (A–E) along the enamel-dentine junction (EDJ) are histologically detailed in (b–f). (b) The micro-organisms (m) penetrate the dentinal tubules (site A). (c) Heavy microbial (m) accumulation is shown along the EDJ gap (\*) (site B). (d, e) Both the microbial (m) accumulation and the size of the EDJ gap (\*) decrease (sites C and D). Arrows show a pattern of the demineralized enamel rod structure. (f) At the outermost affected EDJ area, only the dentine shows alterations in terms of stained demineralization (site E).

have been avoided. The important clinical viewpoint is that it is not the demineralized dentine *per se* that should signal the operative intervention, but the surface integrity of enamel.<sup>13</sup>

#### The cariogenic environment and the cavitated, clinically exposed dentine demineralization

The progression of caries deeper into the dentine is not a one-way, irreversible event, because the carious process is intermittent and the lesion may be slowly or rapidly progressing.<sup>1,2,17</sup> As discussed above, the non-cavitated but demineralized dentine should not trigger operative intervention. Similarly, a cavity which exposes carious dentine is not automatically a sign that operative intervention is required. A comparison between an occlusal and a buccal cavity exposing dentine (Figure 3a–d) illustrates some relevant differences in lesion activity, related to the status of the cavity. In the mandibular molar (Figure 3a), a rather closed ecosystem is shown with a cavity down to the dentine filled with plaque. When the plaque is removed, the dentist can confirm a rapidly progressing lesion,

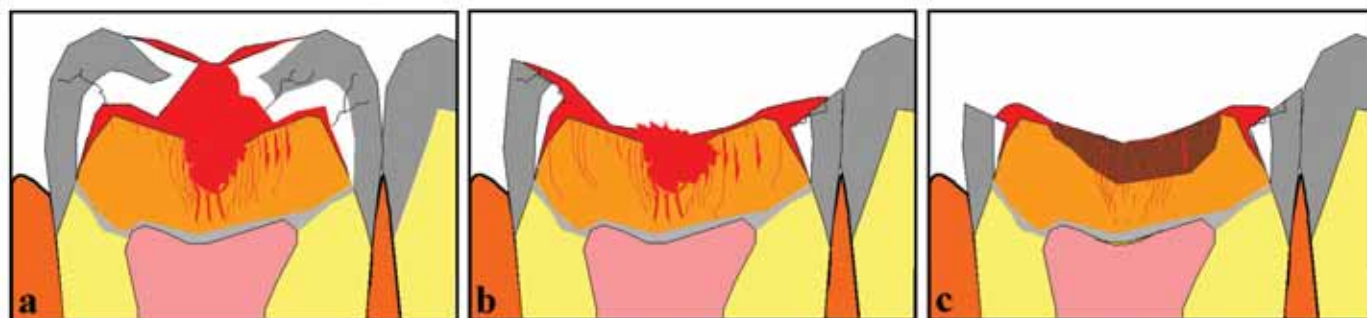
showing a light-brownish discoloration of the soft, wet, demineralized dentine at the bottom of the cavity (Figure 3b). In contrast, smooth surface lesions are, from the start, placed within a more open environment, where the growth of the cariogenic plaque is more often disturbed. This is illustrated by the mandibular canine where surface plaque partly covers the dentine-exposed lesion (Figure 3c). After the plaque removal, a slightly white and dull appearance of the thin enamel margins is noted (Figure 3d), demonstrating that, even within an open lesion environment, the enamel margins have produced a plaque protecting factor, but to a much lesser extent than seen in the occlusal lesion. Finally, the demineralized dentine is dark and often leathery, reflecting the slowly progressing nature of caries at this site. This difference is the result of more effective disturbance of the cariogenic biomasses covering a buccal surface.

In contrast, when a closed and rapidly progressing environment develops, the dentine becomes increasingly infected, and eventually, perhaps owing to shrinkage of the demineralized and necrotic dentine, a new focus of microbial spread starts to appear along the enamel-dentine junction,

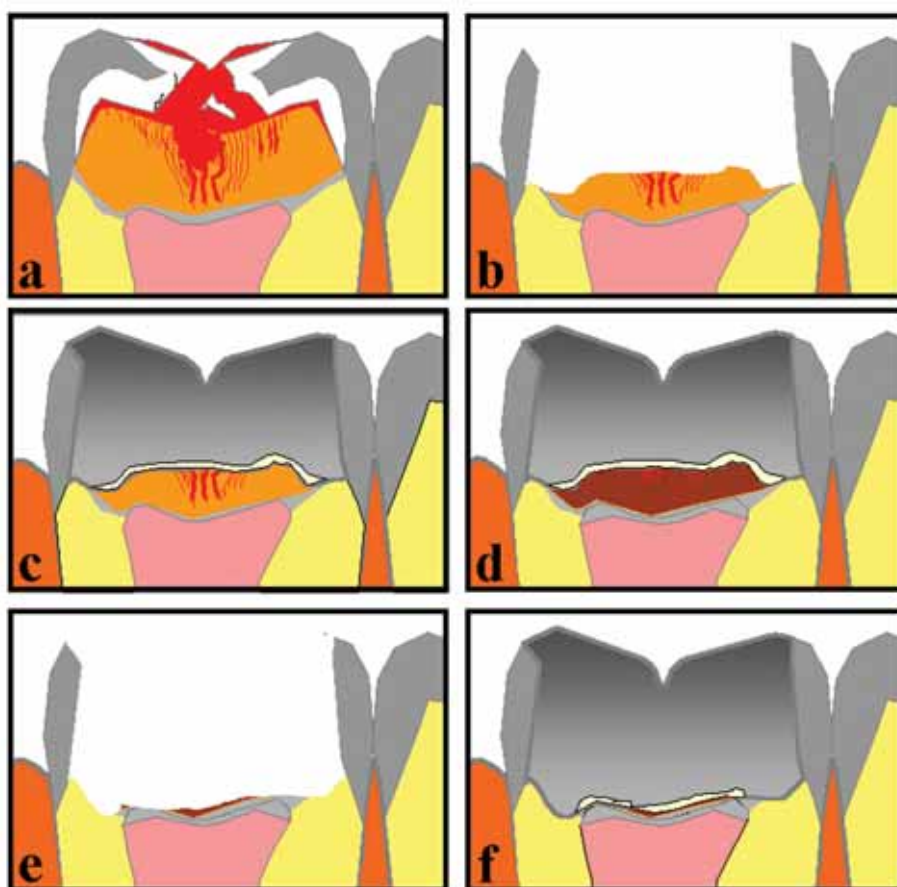
undermining the enamel. The use of undemineralized histological tooth sections nicely demonstrates previous findings from Kidd *et al.*,<sup>18</sup> evaluating bacterial counts at the stained enamel-dentine junction. The bacterial profile actually decreases along the enamel-dentine junction (Figure 4a–f). Moreover, when all the demineralized enamel is removed along the enamel-dentine junction, sound surface enamel is apparent, with no gap and no presence of bacteria further out along the enamel-dentine junction, although the subjacent dentine is demineralized (Figure 4f). Thus, the need for further rigorous removal of the outermost demineralized/stained dentine along the junction is indeed questioned, because micro-organisms (Figure 4f) are not present. When carious dentine is excavated, conventional hand excavation is a very good choice in terms of efficiency and effectiveness, and avoids overpreparation.<sup>19</sup>

#### The cariogenic environment within deep lesions can be altered

Even within deep carious lesions, variations of lesion activity may appear.<sup>20</sup> As the lesion progresses, the enamel breaks



**Figure 5 (a–c).** Diagrams show the temporary conversion of lesion activity during an untreated lesion progress. A closed lesion environment (a). Eventually the white demineralized and undermined enamel breaks owing to mechanical stress, changing the environment into an open ecosystem (b). In the occlusal part signs of slow lesion progress is noted, whereas at the margins active lesion progress continues (c). Red zones indicate plaque. (From Bjørndal<sup>35</sup> reprinted with permission from Blackwell Munksgaard, Oxford.)



**Figure 6 (a–f).** The modified stepwise excavation approach. Red zones indicate plaque. (a) Closed lesion environment. (b) First and less invasive excavation with no focus on pulp close excavation. (c) A calcium hydroxide-containing base material and a provisional restoration. (d) After the treatment interval the carious dentine has clinically changed into signs of slow lesion progress. (e) After final excavation. (f) Permanent restoration. (From Bjørndal<sup>35</sup> reprinted with permission from Blackwell Munksgaard, Oxford.)

5b). In contrast, the peripheral parts are the protected areas, and accumulations of cariogenic biomasses are apparent (Figure 5c). In short, deep dentine-exposed lesions are not unconditionally related to an irreversible pattern of lesion activity, as interpreted in textbooks advocating pulp invasive treatment procedures.<sup>3</sup> Of course, if nothing is done to the deep lesion, even though parts of it are temporarily arrested, the caries process will eventually end up weakening the tooth so that the forces of occlusion may eventually break it apart.

### The modified stepwise excavation approach

The concept of a modified and less invasive stepwise excavation has been developed<sup>17,21</sup> with focus on the conversion of lesion activity (Figure 6). The aim of the first excavation is primarily to make a change within the cariogenic environment, and not to attempt to remove carious dentine to the level of residual caries. Microbiological and clinical studies have shown that the number of bacteria decreases during a treatment interval (6–12 months), and the lesion clinically arrests. The active, soft-yellowish, demineralized dentine turns into a darker, harder and drier demineralized dentine, resembling a slowly progressing lesion, as observed at root-surfaces (Figure 3d). The advantage of this technique should be to reduce the number of iatrogenic pulp perforations performed during the first excavation step. Any attempt to remove ‘most’ of the infected dentine is fraught with danger of exposure. The dentist does not know the distance of

down and, at the same time, the growth conditions for the cariogenic biomasses change. The cavity converts from a closed ecosystem into an open ecosystem (Figure

5a–c). Following the enamel breakdown, the occlusal part of the tooth surface has no heavy plaque accumulation, as the degree of protection has decreased (Figure

the base of the lesion from the pulp. There is currently no way to measure this accurately.

#### Microbiological and clinical changes during a stepwise excavation approach

In a microbiological study on the cultivatable flora in a stepwise excavation model,<sup>22</sup> samples were cultured to recognize specific bacterial groups. Comparisons were made with different clinical features in a limited number of lesions. In particular, closed lesion environments were compared with more open ecosystems. Interestingly, the basic composition of the microflora in each lesion could be seen as a delicate reflection of the clinical characteristics of that particular lesion. In addition, the cultivable flora during a treatment interval changes into a flora representing slow lesion progression, or lesion arrest, findings that have recently gained additional support.<sup>23,24</sup> Whether such a flora can remain beneath a permanent restoration in a deep lesion, and whether demineralization will proceed, needs further investigation.

The increasing knowledge of the clinical and microbiological changes during the treatment provides the clinician with relevant information about the conversion of active to inactive caries. The final excavation is made safer, because it seems to be easier to remove retained, dry carious dentine close to the pulp as compared to the original soft, wet, yellowish demineralized dentine. The final excavation has two aims:

- To verify that arrest has taken place, ie to perform clinical control of the tooth reaction and
- To remove the slowly progressing but still slightly infected discoloured demineralized dentine, before carrying out the permanent and final restoration.

#### Is a two-step excavation necessary?

Indirect pulp capping and stepwise excavation seem very similar techniques, as originally described. Both procedures stress the importance of excavating very close to the wall of the pulp. From the literature it is not possible to know whether there is a difference between the end point of excavation following the traditional indirect pulp-capping procedure, as typically recommended in USA,<sup>25</sup> and the

first excavation within a traditional stepwise excavation procedure.

In a recent practice-based study, general practitioners used a modified and less invasive stepwise excavation (Figure 6), and had pulp complications during final excavation in 5% of the cases.<sup>5</sup> This modified and less invasive stepwise excavation meant that there was no focus on excavating as close to the pulp as possible. In contrast, the use of the older approach<sup>7,8</sup> with a higher focus on caries removal close to the pulp, presented a slightly higher increase in the proportion of pulp complications during the final treatment ( $\approx 15\%$ ). This may be because these latter studies treated more advanced and active lesions, but it might also indicate a positive effect resulting from the less invasive first excavation procedure. More studies are needed to know whether there is an advantage to the less invasive initial caries removal.

Long-term results are available<sup>26</sup> on the consequences of leaving retained carious dentine behind in lesions extending halfway into the dentine on radiograph. These challenge both conventional caries removal and the stepwise concept. However, it is important to underline that the study mentioned did not include deep lesions. Another relevant point is that relatively few patients were available for the late (10-year) control in that study. Actually, there is not yet a high level of evidence among available clinical excavation studies, and therefore it is important that future studies are performed properly as recently addressed in protocols<sup>27,28</sup> and reviews.<sup>29</sup> For the same reasons one could also state that there is no evidence that conventional excavation is needed and several well-controlled studies show it may even be deleterious.<sup>30</sup>

It is tempting to speculate that a large number of pulps have probably been exposed through the years based on the concept that deep carious lesions are always associated with irreversible inflammation, and diagnoses such as asymptomatic pulpitis or chronic pulpitis have been filed. It has somehow always been more accepted to cut overprepared cavities than to leave carious dentine behind. Moreover, a phrase like 'ringing on a sharp probe' has been one of the key learning sentences for decades for many dental students when the golden rules of excavation have been taught. For deep

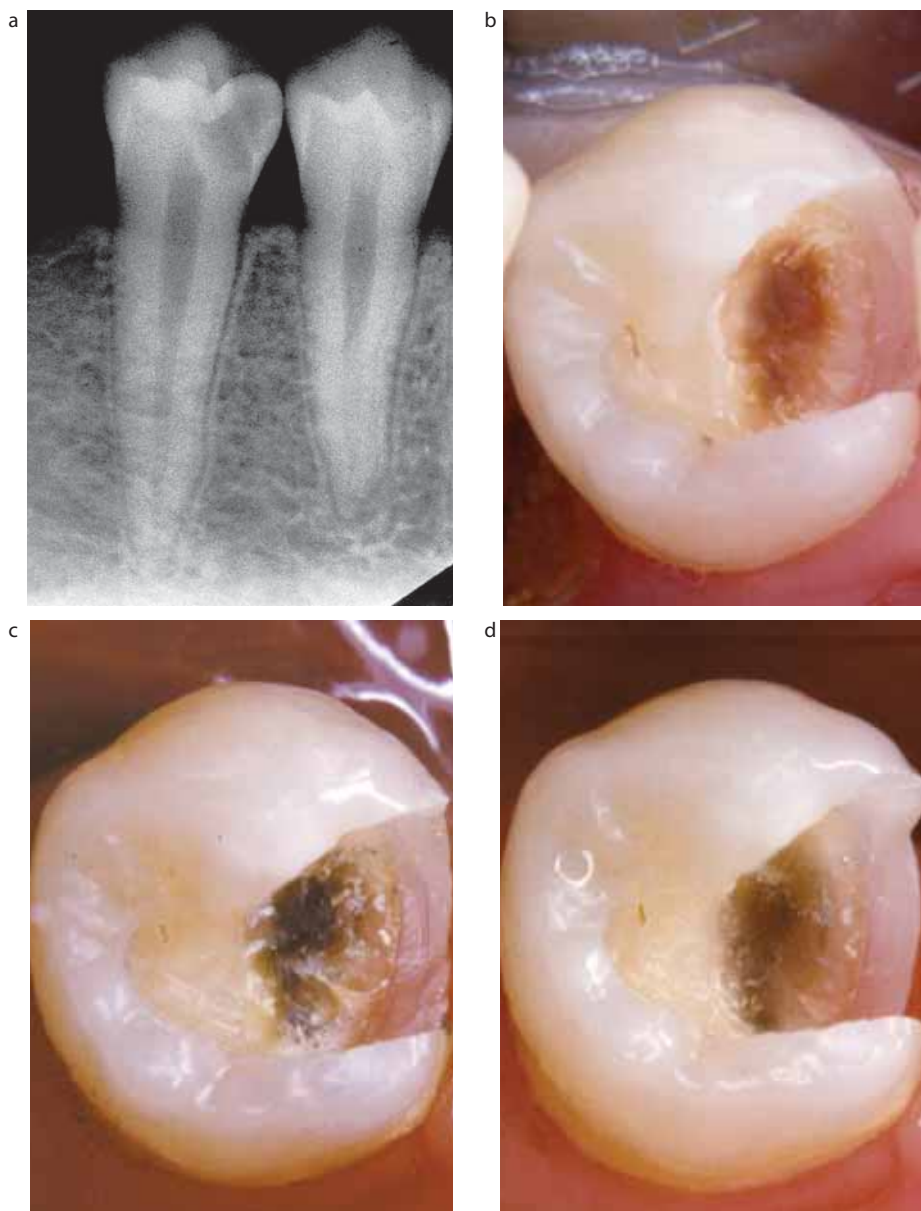
lesion excavation, it has been shown that, by leaving larger amounts of carious dentine behind (maximum period investigated is 1-year),<sup>11,21</sup> the iatrogenic pulp exposure can be avoided, and the final excavation can be performed more easily. Long-term evidence is still lacking in terms of leaving carious dentine permanently behind in deep lesions, therefore the modified stepwise excavation approach is presently recommended by one of us (LB) while the other would not normally re-enter (EAMK). This difference reflects the need for more carefully controlled studies comparing these two approaches.

In summary, the use of knowledge of caries pathology as an integrated part of caries removal is reinforced in a recent textbook chapter,<sup>31</sup> with the conventional wisdom of caries removal being challenged.<sup>32,33</sup>

#### How often is stepwise excavation carried out in Denmark?

In Denmark, there has been an economic agreement between the Danish Dental Association and the Danish National Health Insurance (NHI) where parts of the dental treatment costs for adult patients are funded by the NHI and, in order to receive government fees, the dentists have to report the clinical procedures that have been performed. On this basis, a nationwide database of the performed dental treatments is available, reflecting the dental service pattern from almost all dental practitioners treating adult patients in Denmark. In 1999, the stepwise excavation procedure was introduced in the economic agreement in relation to the treatment of deep carious lesions in the risk zone of pulp exposure. For the last few years, a level between 60 and 70 treatments per 10,000 patients has been reported, and in 2003 a total of 18,610 treatments were performed.<sup>34</sup> Present experience from a dental practice environment has shown the effectiveness of treating deep carious lesions using the modified stepwise excavation, and long term recall (3½–4½ years) has shown a high success rate (92%).<sup>35</sup>

The importance of high quality temporary, as well as permanent restorations, must be stressed, as failures



**Figure 7.** (a) Radiograph of a mandibular premolar with a deep lesion. No evidence of apical pathosis. (b) An overview of the cavity after first excavation following a modified stepwise excavation. (c) After a six month treatment interval and removal of base material and provisional filling (amalgam), the retained carious dentine shows signs of a slow-progressing lesion. (d) Final excavation completed. (From Bjørndal<sup>36</sup> reprinted with permission from *Operative Dentistry*.)

are most often associated with fracture and loss of restorations. Therefore, a two-step excavation procedure will add to the cost of the restorative treatment. Owing to the possibility of asymptomatic development of irreversible pulp degeneration over time, the treatment of deep dentine caries lesions includes a review examination with regard to pulp vitality and apical conditions.

### Tooth selection criteria and clinical comments for stepwise excavation

- Deep lesions considered likely to result in pulp exposure if treated by a single and terminal excavation. Evaluated by radiograph, the lesions involve  $\frac{3}{4}$  or more of the entire dentine thickness (Figure 7a).
- No history of subjective pre-treatment

symptoms such as spontaneous pain and provoked pulpal pain. However, mild to moderate pain upon thermal stimulation is accepted.

- Positive pulp vitality confirmed.
- Pre-treatment radiographs to exclude the possibility of apical pathology.
- Finish the peripheral excavation of the cavity, followed by a central excavation removing only the outermost necrotic and infected demineralized dentine. Now, a provisional restoration can be placed (Figure 7b).
- Avoid excavating close to the pulp during the first step, in order to reduce the risk of pulp exposure.
- Choose the provisional restorative material in relation to the length of the treatment interval, which may range between 6 and 8 months.
- After this treatment interval the retained carious dentine has become darker (Figure 7c), harder and drier.
- The performance of the final excavation often ends up less invasive than expected (Figure 7d), owing to the altered dentinal changes gained during the treatment interval.

### References

1. Bjørndal L, Mjör IA. Dental caries: characteristics of lesions and pulpal reactions. In: *Pulp-Dentin Biology in Restorative Dentistry*, Mjör IA, ed. Chicago: Quintessence, 2002; pp.55–75.
2. Fejerskov O, Kidd EAM. *Dental Caries: The Disease and Its Clinical Management*. Oxford: Blackwell, Munksgaard, 2003.
3. Tronstad L. *Clinical Endodontics* 2nd ed. Stuttgart: Thieme, 2003: 81.
4. Hasselgren G. Treatment of the exposed dentin-pulp complex. In: *Essential Endodontology. Prevention and Treatment of Apical Periodontitis*. Ørstavik D, Pitt Ford TR, eds. Oxford: Blackwell Science, 1998; pp.192–210.
5. Bjørndal L, Thylstrup A. A practice-based study on stepwise excavation of deep carious lesions in permanent teeth. A 1-year follow-up study. *Community Dent Oral Epidemiol* 1998; **26**: 122–128.
6. Kerkhove Jr BC, Herman SC, Klein AI, McDonald RE. A clinical and television densitometric evaluation of the indirect pulp capping technique. *J Dent Child*

- 1967; **34**: 192–201.
7. Magnusson BO, Sundell SO. Stepwise excavation of deep carious lesions in primary molars. *J Int Ass Child* 1977; **8**: 36–40.
  8. Leksell E, Ridell K, Cvek M, Mejäre I. Pulp exposure after stepwise versus direct complete excavation of deep carious lesions in young posterior permanent teeth. *Endod Dent Traumatol* 1994; **12**: 192–196.
  9. Sowden JR. A preliminary report on the recalcification of carious dentin. *J Dent Child* 1956; **23**: 187–188.
  10. Law DB, Lewis TM. The effect of calcium hydroxide on deep carious dentin. *Oral Surg Oral Med Oral Path* 1961; **14**: 1130–1137.
  11. Eidelman E, Finn SB, Koulourides T. Remineralization of carious dentine treated with calcium hydroxide. *J Dent Child* 1965; **32**: 218–225.
  12. Ricketts DNJ, Ekstrand KR, Kidd EAM, Larsen T. Relating visual and radiographic ranked scoring systems for occlusal caries detection to histological and microbiological evidence. *Oper Dent* 2002; **27**: 231–237.
  13. Thylstrup A, Qvist V. Principal enamel and dentine reactions during caries progression. In: *Dentine and Dentine Reactions in the Oral Cavity*. Thylstrup A, Leach SA, Qvist V, eds. Oxford: IRL Press, 1987; pp.3–16.
  14. Bjørndal L, Thylstrup A. A structural analysis of approximal enamel caries lesions and subjacent dentin reactions. *Eur J Oral Sci* 1995; **103**: 25–31.
  15. Bjørndal L, Darvann T, Lussi A. A computerized analysis of the relation between the occlusal enamel caries lesion and the demineralized dentin. *Eur J Oral Sci* 1999; **107**: 176–182.
  16. Ekstrand KR, Ricketts DNJ, Kidd EAM. Do occlusal carious lesions spread laterally at the enamel-dentin? A histopathological study. *Clin Oral Invest* 1998; **2**: 15–20.
  17. Massler M. Treatment of profound caries to prevent pulpal damage. *J Pedod* 1978; **2**: 99–105.
  18. Kidd EAM, Joyston-Bechal S, Beighton D. Microbiological validation of assessments of caries activity during cavity preparation. *Caries Res* 1993; **27**: 402–408.
  19. Banerjee A, Kidd EAM, Watson TF. *In vitro* evaluation of five alternative methods of carious dentine excavation. *Caries Res* 2000; **34**: 144–150.
  20. Edwardsson S. Bacteriology of dentin caries. In: *Dentine and Dentine Reactions in the Oral Cavity*. Thylstrup A, Leach SA, Qvist V, eds. Oxford: IRL Press, 1987; pp.95–102.
  21. Bjørndal L, Larsen T, Thylstrup A. A clinical and microbiological study of deep carious lesions during stepwise excavation using long treatment intervals. *Caries Res* 1997; **31**: 411–417.
  22. Bjørndal L, Larsen T. Changes in the cultivable flora in deep carious lesions following a stepwise excavation procedure. *Caries Res* 2000; **34**: 502–508.
  23. Paddick JS, Brailsford SR, Kidd EAM, Beighton D. Phenotypic and genotypic selection of microbiota surviving under dental restorations. *Appl Environ Microbiol*; 2005; **71**: 2467–2472.
  24. Maltz M, de Oliveira EF, Fontanella V, Bianchi R. A clinical, microbiologic, and radiographic study of deep caries lesions after incomplete caries removal. *Quintessence Int* 2002; **33**: 151–159.
  25. Dumsha T, Hovland E. Considerations and treatment of direct and indirect pulp-capping. *Dent Clin North Am* 1985; **29**: 251–260.
  26. Mertz-Fairhurst EJ, Curtis JW, Ergle JW, Rueggerberg FA, Adair SM. Ultraconservative and cariostatic sealed restorations: Results at year 10. *J Am Dent Assoc* 1998; **129**: 55–66.
  27. Nadin G, Goel BR, Yeung Ca, Glenny AM. Pulp treatment for extensive decay in primary teeth (Cochrane Review). In: *The Cochrane Library*, Issue 1, 2004. Chichester, UK: John Wiley & Sons, Ltd.
  28. Ricketts DNJ, Kidd EAM, Innes N. Complete or ultraconservative removal of decayed tissue in unfilled teeth (Protocol for a Cochrane Review). In: *The Cochrane Library*, Issue 1, 2004. Chichester, UK: John Wiley & Sons, Ltd.
  29. Bergenholtz G, Spångberg L. Controversies in endodontics. *Clin Rev Oral Biol Med* 2004; **15**: 99–114.
  30. Kidd EAM. How 'clean' must a cavity be before restoration? *Caries Res* 2004; **38**: 305–313.
  31. Kidd EAM, Fejerskov O, Mjör IV. Caries removal and the pulpo-dentinal complex. In: *Dental Caries: The Disease and Its Clinical Management*. Fejerskov O, Kidd EAM, eds. Oxford: Blackwell, Munksgaard, 2003; pp.267–274.
  32. Kidd EAM. Caries removal and the pulpo-dentinal complex. *Dent Update* 2000; **27**: 476–482.
  33. Ricketts D. Management of the deep carious lesion and the vital pulp dentine complex. *Br Dent J* 2001; **191**: 606–610.
  34. Bjørndal L, Reit C. The annual frequency of root-fillings tooth extractions and pulp related procedures in Danish adults 1977–2003. *Int Endod J* 2004; **37**: 782–788.
  35. Bjørndal L. Dentine and pulp reactions to caries and operative treatment: biological variables affecting treatment outcome. *Endodontic Topics* 2002; **3**: 123–136.
  36. Bjørndal L. Dentine caries: Progression and clinical management. Buonocore Memorial Lecture. *Oper Dent* 2002; **27**: 211–217.

## COVER PICTURES

Do you have an interesting and striking colour picture with a dental connection, which may be suitable for printing on the front cover?

Send your pictures to:

The Executive Editor, *Dental Update*

George Warman Publications (UK) Ltd, Unit 2, Riverview Business Park, Walnut Tree Close, Guildford, Surrey GU1 4UX

Payment of £100 will be made on publication.